# BURN SCAR LIPOFILLING: IMMUNOHISTOCHEMICAL AND CLINICAL OUTCOMES


## Abstract

Over the past years, lipofilling has been used for many pathologies and sequelae; recently, its use has also widened for burn outcomes. 93 burn scars were assessed (from September 2011 to February 2012). Half scar area was treated with injection of adipose tissue harvesterd from subcutaneous fat and processed according to Colamn's technique. Biopsies were taken before treatment and at 3 and 6 months post-operative. Histological and immunohystochemical evaluation were conducted. In the samples examined, a marked improvement was observed, which can be seen in three months, but most of all documented at six months; also from a clinical point of view, an improvement has been documented both functional and aesthetic.Lipofilling for burn scar complete and improve the results of standard surgical procedures, with long-setting and acting results.


## Introduction

Hypertrophic burn scars occur in about 75% of Caucasian patient, as a result of third degree burns (1). They lead to a great number of adverse consequences such as loss of function or altered appearance (2). Study have begun to reveal the process of intercellular communication that regulate this process of burn scar development (3). In the majority of affected cases these hypertrophic scars gradually improve over a period of a few years. The final largest hypertrophic scars are surgically excised often with creation of Z plasties or skin grafts to release scar contractures.

The sub scar and intra scar fat grafting is a relatively recent technique that allows the improvement of the quality of the scar as clinically evaluated from the modified Vancouver Scar Scale.

This article investigates the processes of modification of scar tissue induced by fat grafting.

## Materials and Methods

For our study, burn scars of at least 200cm2, divided into two homogeneous portions were selected.
In area A lipofilling was performed, through an intra scar infiltration, the second half of the scar area (named B) was the control one.

93 burn scars were assessed (from September 2011 to February 2012), the mean age of the scar was 2.3 years (range from 8 months to 29 years ), we chose an adult population (mean 43 years, range 18 to 92 years). Biopsies of the two areas (A and B) were conducted by a 0.8 cm punch, at three different times: before treatment, after 3 and 6 months of treatment.
The biopsies were placed, immediately after their collection, in 10% saline-buffered formalin, so as to prevent autolytic putrefactive phenomena. After fixation, the tissue samples were vigorously


**presented at the 61 Annual Meeting of the Italian Society of Plastic Surgery (SICPRE), - Panel on lipofilling - Palermo 24th-27th September 2012.**

rinsed to remove excess fixative and were then dehydrated, clarified and included. The samples included were cut with a sliding microtome and placed on polarized glass slides.

Six histochemical stains were performed:
1. Hematoxylin-eosin to assess nuclear and cytoplasmic structure of the cells;
2. Masson Fontana, to evaluate melanocytic activity;
3. Unna, to evaluate the elastic fibers, stained in red together with mast cells, while other fibers in blue;
4. SGM (Silver Gomori Methenamina), to evaluate the basal membrane;
5. WEF (Weigert Elastic Fibers), to evaluate the elastic fibers;
6. Weigert Van Gieson to assess the elastic fibers and connective tissue (rapid method) (Bio-Optica)

Immunohistochemical stainings were also conducted, using the following antibodies:
1. Ki-67 to assess the proliferation index (Dako, TEC, 1:100); (4)
2. VEGF, to assess angiogenesis (Santacruz; Citrate; 1:100); (5)

3. P63, to assess cell proliferation (Santacruz; Citrate; 1:200); (6)
4. P53, to assess inhibition of cell growth (Dako; TEC; 1:50); (7)
5. S100, to evaluate cell differentiation and melanin (Dako, citrate, 1:100); (8)
6. Monoclonal Langerin, to evaluate the Langerhans cells (ylem; Citrate; 1:100); (9)
7. B-catenin, to evaluate the stabilization of the cytoskeleton and the stability of cell junctions (Dako; Citrate; 1:100); (10)
8. TGF-β, to evaluate the fibrotic response and neo vascularization (Ylem; citrate; 1:20). (7)

The adipose tissue, necessary for the lipofilling procedure, was collected from the abdomen, hips, trochanteric region, inner thigh, medial aspect of the knees. A super-wet technique was used with anesthetic solution infiltration (Ringer-Lactate with Ropivacaine 2% and epinephrine 1/500000). Adipose tissue was therefore aspirated by means of a two holes blunt cannula, of three mm internal diameter, connected to a 10cc luer-lock syringe; a gentle negative pressure was carried out, gradually retracting the syringe plunger.
The adipose tissue thus obtained was centrifuged at 3000 rpm for three minutes, afterwards we removed the upper (oil) and lower (blood and liquid infiltration) layers. The central layer, consisting of purified fat, was transferred, through a collector, to a 1 or 3 cc luer-lock syringes.
The infiltration occurred in the sub scar layer, where beads of adipose tissue were placed, but mainly in the intra-scar plane.
To this purpose, the blunt Coleman cannulas were detected ineffective to allow adequate infiltration, because of the compactness of the scar; we therefore used a sharp angiographic cannula, that allow us to easily overcome tissue resistance, so enabling grafting of the purified fat directly into the scar. It may also be argued that the sharp instrument may stimulate a normal collagen deposition, similar to the needling procedure. (11)

## RESULTS

### Hematoxylin-eosin (H & E)

In the scar tissue, before any kind of treatment, a good melanocytic activity is observed; the basal layer is evident, less evident is instead the granulous layer.
In the connective tissue one can see a thickened collagen and the absence of hyperkeratinization. 6 months post treatment, there is a collagen eruption and apparently better vascularization of the dermal papillae which are now clearly visible. The collagen, chaotically organized in the pre-treatment, appears more organized with parallel fibers. **(Fig 1 A, C, E, pre-operative; B,D,F post-operative)**

### Masson Fontana

In the pre-treatment biopsy there is a strong appreciable marking at the dermal-epidermal junction which highlights a large number of positive melanocytes. This situation appears to be strongly reduced as a result of the lipofilling treatment. The reduction is not present in the control areas, where we found an unchained melanocytic activity. **(Fig 2 A and B Pre-operative; C and D post-operative)**

### WFE + Tri-Gomori

Following lipofiling treatment, there is an increased number of elastic fibers that make the collagen finely fibrillar. The collagen appears more cellular and compact and the appearance of vessels is observed. **Fig 3 A pre-operative; B post-operative**

### Unna

After the treatment, the collagen fibers increase in the dermo-papillary layer, that is the most superficial reticular dermis. **Fig 4 C pre-operative; D post-operative.**

### Silver Gomori Methenamina (SGM):

A change in the organization is observed. The level of organization of the connective tissue improves in the treated tissue, but there is also an improvement in the fibrillar organization which is best evident after 6 months. After the treatment, the papillary dermis seems to reappear. The collagen, initially thickened, becomes more fibrillar. **Fig 5 E pre.operative; F post-operative**

### Weigert Van Gieson

Before treatment, the elastic fibers are very thin, short, not very representative and confined to the mid superficial reticular dermis. In fact, elastic fibers are almost absent in the epithelium, concentrate primarily in the superficial dermis to decrease again as one deepens.
After 6 months the increase in elastic fibers is also evident in the epithelium; in the deeper layer, one can find thinner ones as the collagen is more fibrillated. **Fig 6 A and C pre-treatment; B and D post-treatment**

### S-100

In the pre-treatment status, there is a high number of melanocytes at the basal membrane level. At this level there are also dendritic cells or Langerhans cells, whose number is decreased in the

tissue after 6 months of treatment. This staining also reveals nerve endings, as S-100 is a Calcium-binding protein. **Fig 7 A pre-treatment; B post-treatment**

**Langerin**

In the pre-treatment, the Langerhans cells are many and positive; after 6 months of treatment, the tissue becomes negative.

Because of the thermal damage suffered by the skin, there appears an erithematous zone with Langerhans cells. These cells are APC ( Antigen Presenting Cells) and are recalled in the epithelium; here they remain trapped in the area of thickened scar connective tissue, only after the treatment connective tissue becomes looser and Langerhans cells tend to disappear, migrating downwards. **Fig 8 C pre-treatment; D post-treatment.**

The cell count of S-100 and Langerin highlights the evident decrease of Langerhans cells, after treatment. This observation is also confirmed by the Wilcoxon test which results in a probability (P) equal to 0.005 for S-100 and 0.0043 for Langerin, both highly significant. **Table 1 and 2**

**P53**

Comparing the pre-operative and 6-months post-operative tissue, there appears an increased positivity following treatment, showing intense proliferative activity at the level of the basal and spinous layer.

**P63**

In the pre-treatment sample there is a diffuse proliferative activity widespread in many layers of the epithelium. At 6 months after treatment, there is a lower proliferative activity restricted at the level of the basal layer. So where cell proliferation increases, P53 increases and P63 decreases. This behavior is due to the fact that the expression of P63 is connected to a maturation block. After treatment P63 is expressed in the germinal layer and disappears in the upper layers as in healthy skin. P53 is not expressed in the scar tissue before treatment because it is blocked by P63 expression. **Fig.9 A P53 pre-operative; B P53 post-operative; C P63 pre-operative; D P63 post-operative.**

**Ki-67**

Ki67 is a nuclear antigen expressed by proliferating cells..

in the pre-treatment status its expression is negative, while after lipofilling treatment, one can observe many positive cells at the level of the basal layer. **Fig.10 E pre-operative F post-operative**

The cell count of P53, Ki-67 and P63 and the probability calculated with the Wilcoxon test confirm the trend of proliferative activity and its significance. **Table 3, 4, 5.**

**VEGF**

In the untreated scar VEGF is expressed mainly from melanocytes and keratinocytes; after treatment, it is no longer expressed.

The scar tissue after 6 months of treatment tends to assume a nearly normal morphology. **Fig. 11 A pre-operative, B post-operative**

**presented at the 61 Annual Meeting of the Italian Society of Plastic Surgery (SICPRE), - Panel on lipofilling - Palermo 24th-27th September 2012.**

**TGF-β**

Before treatment there is positivity in the epithelium layer, while after 6 months there is a net decrease. The positive epithelium can be attributed to its attempt to repair; after lipofilling is performed, its expression disappears. In the dermis, initially there are fibroblast-like cells that tend to disappear after treatment. **Fig.12 C pre-operative, D post-operative**

**β-catenin**

In the untreated scar tissue, the β-catenin is expressed predominantly in the spinous layer, at membrane level and the cell junctions; while it is not observed at the basal layer. After 6 months of treatment, however, there is a down-regulation. Thus the treatment reduces the expression of β-catenin. **Fig. 13 E pre-operative, F post-operative.**

**DISCUSSION**

As revealed by these immunohistochemical studies, burn scar, even old ones, cannot be considered as a quiescent scar, as they are characterized by a maturation block, a pro-inflammatory and hypervascularized status.
Lipofilling allows a dramatic change of this status making the tissue much more similar to the healthy one, also from an histological point of view.
The positivity of VEGF, β-catenin and TGF-β that will be down-regulated after treatment, may be associated to the restitutio ad integrum of the tissue, as well as the considerable amount of Langerhans cells that are lost after the treatment, a phenomenon due to their nature of Antigen Presenting Cell (APC), called in the epithelium in defense of the damaged skin and trapped in the scar because of the very dense connective.

The index of cellular proliferation evaluated by Ki-67, is also highly significant; this is due to the ADSC that once infiltrated at the level of the scar through the lipofiling technique, engraft and proliferate, thus regenerating a normal environment.

The expression of P53 and the inhibition of P63 are connected. The expression of P63 is closely confined in the nucleus and is required to maintain the function of proliferative potential, differentiation and regeneration of the epidermis; while inhibition of cell proliferation resulting from the loss of P63 is P53-dependent, the defects of cell differentiation appear to be independent from P53. Conversely P53 is not expressed in the scar tissue because it is blocked by the expression of P63, connected to a cell maturation block.

After complete healing, P63 is still widely expressed not only in the basal keratinocytes, but also within the spinous layer, whereas the expression of Ki-67 is confined to individual cells of the basal layer. Apparent migration is activated , prot
From the clinica mprove both functional and a

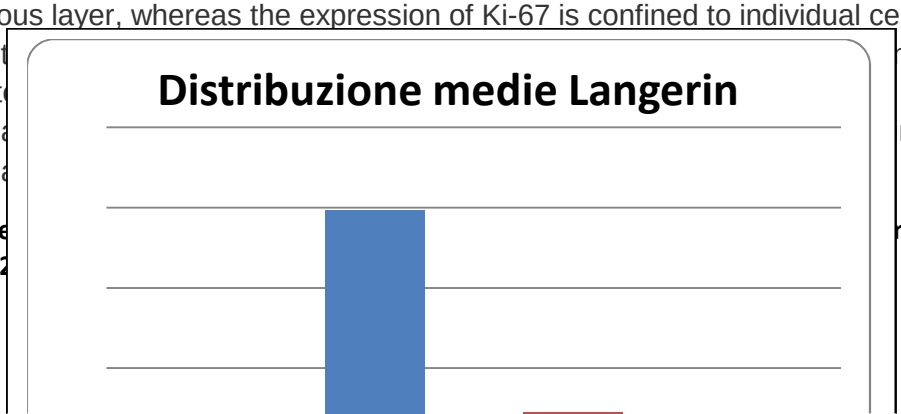


**presented at the nel on lipofilling - Palermo 24th-2**

For the objective clinical evaluation of patients we used a modified Vancouver scar scale. (12) The assessment was carried out at time 0, that is, before any type of treatment and at three and six months.
We evaluated vascularization, the pigmentation, plicability, thickness, and the relief on the skin surface. These features have been selected on the basis of clinical experience and literature. each item provides a partial score up to 10, with 10 indicating the worst scar. Therefore, the final score is the sum of the partial scores of each item.
The lowest score, namely 5, indicates normal skin, while a score of 50 suggests the worst imaginable scar.
A double blind assessment has been provided, carried out by doctors who were not part of the study.

The average score of the objective pre-treatment was 41 (range 34 to 49), three months after treatment was 29 (range 22 to 35) and six months after treatment was 15 (range 9 to 18).
It was found that the improvement, although present also at three months after treatment, reaches the apex at six; this aspect is also parallel to the histological evaluations carried out, since the maximum histologic improvement was shown at six months.
This suggests that lipofiling provides a long-acting, slowly-occurring effect, triggering histological changes that reach the maximum level six months after treatment. This also suggests to wait 5-6 months before taking into account the occurrence of a new treatment.

We also provide a subjective evaluation: we valued appearance, symptoms, awareness of the scar, satisfaction in appearance, satisfaction about the symptoms. The questionnaire was given at time 0, three and six months. The total score is the sum of the individual items, each of which provides a partial score.
The questionnaire oscillates from a minimum score of 28 (maximum degree of dissatisfaction) to a maximum score of 112 (maximum degree of satisfaction).
At time 0, the average score was 31 (range 26 to 38); at three months was 64 (range 47 to 72) and six months was 95 (range 81 to 102). We therefore documented, also in the subjective test, an improvement that reaches the maximum degree at six months. **Fig.14, 15, 16.**

We confirm, therefore, the value of the lipofillng treatment for the improvement of burn scar sequelae, as already emerged from previous studies. (13)
Intra-scar infiltration allows, however, better results, since we are able to bring the ADSC directly into a tissue that would otherwise be too firm for their diffusion.

**presented at the 61 Annual Meeting of the Italian Society of Plastic Surgery (SICPRE), - Panel on lipofilling - Palermo 24th-27th September 2012.**